



192.168.6.2/Forms/Exan

**Personal information****Student**Shahzeb
Hassan**Reg No**

MB1924-1991

Scope

scope

Timer

01:31:16

Q#120

A 29 years old man presents with anemia, bleeding tendency, diarrhea and abdominal pain. On examination he is having a palpable mass in the right lower quadrant and anal skin tags. What is the most likely underlying condition?

- ☐ Chronic pancreatitis
- ☐ Celiac disease
- ☐ Crohn's disease
- ☐ Intestinal lymphoma
- ☐ Ulcerative colitis

PREVIOUS

FINISH

**Important Note**

- Finishing test is mandatory, exit in the mid of the test will mark the student as absent.
- If you are uploading multiple files, first zip it.
- 01:26



192.168.6.2/Forms/Exan

**Personal information****Student**Shahzeb
Hassan**Reg No**

MB1924-1991

Scope

scope

Timer

01:53:03

Q#11

A 10 year old child presents with the history of frequent staring spells. The child does not recall anything after these spells have occurred. His school performance is poor. You get an EEG done which shows 3 spikes per second. Which of the following is the drug of choice for this child's condition?

- ☐ Ethosuximide
- ☐ ACTH
- ☐ Prednisolone
- ☐ Valproate
- ☐ Lamotrigine

PREVIOUS

NEXT

**Important Note**

- Finishing test is mandatory, exit in the mid of the test will mark the student as absent.
- If you are uploading multiple files, first zip it.
- 01:06



Personal information

Student

Shahzeb
Hassan

Reg No

MB1924-1991

Scope

scope

Timer

01:31:42

Q#116

You see a 55 year old female, with an established diagnosis of Paranoid Schizophrenia. She has been on anti psychotic medications since the last 30 years and has been functioning well when compliant with medications. She is a principal at the local school and enjoys her job. Since the last few months, she has been noticing involuntary and unusual movement in her orofacial region. These are described by the family as if she is smacking her lips following eating something bitter. You observe her to be constantly chewing also, despite having nothing in her mouth. What would be your most likely diagnosis?

- ☐ Acute Dystonia
- ☐ Akathesia
- ☐ Parkinsonism
- ☐ Torticollis
- ☐ Tardive dyskinesia

PREVIOUS

NEXT



Important Note

- Finishing test is mandatory, exit in the mid of the test will mark the student as absent.
- If you are uploading multiple files, first zip it.
- 01:26

**Personal information****Student**Shahzeb
Hassan**Reg No**

MB1924-1991

Scope

scope

Timer

01:59:08

Q#2

A 60-year-old Male was brought to the ER who is a known case of Diabetes and hypertension, with sudden onset of left sided weakness and aphasia for the last 03 hours. Examination showed hypertonia, decreased power and upgoing plantars on left sided. CT brain showed right middle cerebral artery infarct. What should be the most appropriate management step?

- ☐ Anticoagulation
- ☐ Thrombolytic therapy (Alteplase)
- ☐ Thrombectomy
- ☐ Antiplatelets therapy
- ☐ None of the above

PREVIOUS

NEXT

**Important Note**

- Finishing test is mandatory, exit in the mid of the test will mark the student as absent.
- If you are uploading multiple files, first zip it.
- 01:06



192.168.6.2/Forms/Exan

**Personal information****Student**Shahzeb
Hassan**Reg No**

MB1924-1991

Scope

scope

Timer

01:58:40

Q#3

A 10 years old child presents with recurrent episodes of headache for the last one year. Sometimes the headache is felt over the left eye and throbbing in nature and preceded by blind spots in visual fields. Physical examination and neuroimaging did not reveal any abnormality. The most likely diagnosis is:

- ☐ Tension headache
- ☐ Tuberculous meningitis
- ☐ Pseudotumor cerebri
- ☐ Migraine
- ☐ Posterior fossa tumor

PREVIOUS

NEXT

**Important Note**

- Finishing test is mandatory, exit in the mid of the test will mark the student as absent.
- If you are uploading multiple files, first zip it.
- 01:06



192.168.6.2/Forms/Exan

**Personal information**

Student

Shahzeb
Hassan

Reg No

MB1924-1991

Scope

scope

Timer

01:53:41

Q#10

A 38-year-old woman comes to the clinic for regular checkup. She complains of lethargy and feels feverish for the last one month. She is originally from Afghanistan and married for the past 12 years. She has no significant past medical history except a blood transfusion for her C-Section two years ago. Physical examination is unremarkable. Her investigations showed raised ALT and AST. Further workup showed: Hepatitis A IgG positive Hepatitis B surface antigen positive Hepatitis B e antigen positive Anti-hepatitis B virus core IgG positive Hepatitis C IgG negative HBV DNA level is 48×10^6 IU/mL. Which of the following medications is indicated for this patient?

- ☐ Acyclovir
- ☐ Entecavir
- ☐ No treatment is necessary
- ☐ Ritonavir
- ☐ Simeprevir

PREVIOUS

NEXT

**Important Note**

- Finishing test is mandatory, exit in the mid of the test will mark the student as absent.
- If you are uploading multiple files, first zip it.
- 01:06

**Personal information****Student**Shahzeb
Hassan**Reg No**

MB1924-1991

Scope

scope

Timer

01:55:32

Q#7

A newborn presented to you on first day of life with abdominal distension and bilious vomiting. On examination there is no anal opening. A diagnosis of anorectal malformation is made. Which of the following investigation will identify between low and high type of anorectal malformation?

- ☐ Ultrasound abdomen
- ☐ ECHO
- ☐ MRI pelvis
- ☐ CT abdomen and pelvis
- ☐ Prone Cross table lateral X-ray

PREVIOUS

NEXT

**Important Note**

- Finishing test is mandatory, exit in the mid of the test will mark the student as absent.
- If you are uploading multiple files, first zip it.
- 01:06

**Personal information****Student**Shahzeb
Hassan**Reg No**

MB1924-1991

Scope

scope

Timer

01:31:37

Q#117

A 30 years old man presents with acute,profuse ,watery diarrhea with some blood after returning from a holiday in Tanzania.He had been taking oral rehydration salts.Which one of the following is the most appropriate treatment?

- ☐ Ciprofloxacin
- ☐ Loperamide
- ☐ Metronidazole
- ☐ Prednisolone
- ☐ Vancomycin

PREVIOUS

NEXT

**Important Note**

- Finishing test is mandatory, exit in the mid of the test will mark the student as absent.
- If you are uploading multiple files, first zip it.
- 01:26



192.168.6.2/Forms/Exan

**Personal information****Student**Shahzeb
Hassan**Reg No**

MB1924-1991

Scope

scope

Timer

01:31:50

Q#115

A 12-month-old child comes to your OPD with chief complaint of poor weight gain. The child started to have loose stools at the age of 6 months and has a very poor appetite. On examination, you see a pale and irritable child with very little subcutaneous fat and a distended abdomen. He isn't jaundiced, tachypneic or tachycardiac. His urine output is normal and on examination there is no involvement of any other system. What is the most probable diagnosis?

- ☐ celiac disease
- ☐ cystic fibrosis
- ☐ inflammatory bowel disease
- ☐ acute gastroenteritis
- ☐ cholera

PREVIOUS

NEXT

**Important Note**

- Finishing test is mandatory, exit in the mid of the test will mark the student as absent.
- If you are uploading multiple files, first zip it.
- 01:26



192.168.6.2/Forms/Exan

**Personal information****Student**Shahzeb
Hassan**Reg No**

MB1924-1991

Scope

scope

Timer

01:31:21

Q#119

A 25-year-old female presented to the OPD with quadreplegia. Weakness started in the lower limb progressing to the upper limb with in a week. It was preceded by food poisoning. On examination there is hypotonia with decreased power in all the limbs and lost reflexes. Labs are normal. What can be the probable diagnosis?

- ☐ Multiple sclerosis
- ☐ Transverse myelitis
- ☐ Gullian barre syndrome
- ☐ Conversion disorder
- ☐ Hypokalemic periodic paralysis

PREVIOUS

NEXT

**Important Note**

- Finishing test is mandatory, exit in the mid of the test will mark the student as absent.
- If you are uploading multiple files, first zip it.
- 01:26



192.168.6.2/Forms/Exan

**Personal information****Student**Shahzeb
Hassan**Reg No**

MB1924-1991

Scope

scope

Timer

01:57:41


Q#4

A 46-year-old woman with multiple sclerosis for 30 years complained of overwhelming fatigue. She said that despite sleeping well she needed to nap daily and had trouble focusing on books and TV programs. Which of the following medications might help this patient?

- ☐ Carbamazepine
- ☐ Dalfampridine
- ☐ Venlafaxine
- ☐ Modafinil
- ☐ Dextromethorphan hydrobromide and quinidine sulfate

PREVIOUS

NEXT

**Important Note**

- Finishing test is mandatory, exit in the mid of the test will mark the student as absent.
- If you are uploading multiple files, first zip it.
- 01:06



192.168.6.2/Forms/Exan

**Personal information****Student**Shahzeb
Hassan**Reg No**

MB1924-1991

Scope

scope

Timer

01:56:03


Q#6

9 month old infant presented to you with complain of enlarged head size and swelling on lower back as well since birth. His parents also complain of fever and vomiting on and off. After examination and investigation you made a diagnosis of hydrocephalus with meningomyelocele. What treatment option will you adopt first in this patient?

- ☐ A. VENTRICULECTOMY
- ☐ B. VENTRICULOPERITONEAL SHUNT (VP SHUNT)
- ☐ no need to intervene
- ☐ meningocele repair
- ☐ conservative management

PREVIOUS

NEXT

**Important Note**

- Finishing test is mandatory, exit in the mid of the test will mark the student as absent.
- If you are uploading multiple files, first zip it.
- 01:06



192.168.6.2/Forms/Exan

**Personal information****Student**Shahzeb
Hassan**Reg No**

MB1924-1991

Scope

scope

Timer

01:59:13

Q#1

A 56-year-old lady gets admitted with abdominal pain and vomiting. The patient is a known case of Hepatitis C and her liver disease has progressed, and she has developed liver cirrhosis on ultrasound abdomen. Physical examination had pale cachectic lady with blood pressure of 100/60 mm Hg, heart rate 96/min and afebrile. Which of the following will be the most likely cause of death in this patient?

- ☒ Bleeding varices
- ☐ Coagulopathy
- ☐ Encephalopathy
- ☐ Hepatocellular carcinoma
- ☐ Renal failure

NEXT

**Important Note**

- Finishing test is mandatory, exit in the mid of the test will mark the student as absent.
- If you are uploading multiple files, first zip it.
- 01:06



192.168.6.2/Forms/Exan



Personal information

Student

Shahzeb
Hassan

Reg No

MB1924-1991

Scope

scope

Timer

01:49:08

Q#17

A 50 year old man presented with episodes of altered behavior. During these episodes, which occurred when he was sleeping, the patient developed a "blank look" and violently kicked his legs like he was "riding a bicycle." Each episode lasted about 30 seconds and he was confused afterward with no memory of the event. Imaging is most likely to reveal an abnormality in what area of the brain?

- ☐ Thalamus
- ☐ Frontal lobe
- ☐ Lateral temporal lobe
- ☐ Parietal lobe
- ☐ Occipital lobe

PREVIOUS

NEXT



Important Note

- Finishing test is mandatory, exit in the mid of the test will mark the student as absent.
- If you are uploading multiple files, first zip it.
- 01:16



192.168.6.2/Forms/Exan

**Personal information****Student**Shahzeb
Hassan**Reg No**

MB1924-1991

Scope

scope

Timer

01:50:35

Q#15

You see a 50 year old land owner on the medical ward. He has been using alcohol in excess since the last few years and finally wants to come off it completely. He has tried a few detoxification and rehabilitation centers in the past but has not been successful so far in coming off this substance. He feels that substitute medication, however effective it is, is not a sustainable option and would like to know more about what other therapies can be tried along with them. What other therapies can be used for helping him break his dependency?

- ☐ Guidelines recommend using medications for symptomatic relief only
- ☐ Guidelines recommend using two or more abstinence achieving medications in combination for such cases
- ☐

Guidelines recommend using abstinence achieving medications, motivational enhancement therapy, and weekly face to face counseling



Guidelines recommend using abstinence achieving medications, motivational enhancement therapy, support groups and internet based counseling

- ☐ Guidelines recommend using abstinence achieving medications only, as research for other therapies is lacking

PREVIOUS

NEXT

**Important Note**

- Finishing test is mandatory, exit in the mid of the test will mark the student as absent.
- If you are uploading multiple files, first zip it.
- 01:06



192.168.6.2/Forms/Exan

**Personal information****Student**Shahzeb
Hassan**Reg No**

MB1924-1991

Scope

scope

Timer

01:52:45

Q#12

A 48 year old man presents with haematemesis and malena.He admits to high alcohol intake.On examination he is shocked ,his heart rate is 110 beats per minute and blood pressure is 92/74 mm-Hg.There is evidence of leukonychia and abdominal examination reveals tenderness in the epigastrium.What is the most likely underlying cause of the gastrointestinal hemorrhage?

- ☐ Gastroesophageal varices
- ☐ Mallory Weiss tearPeptic ulceration
- ☐ Portal hypertensive gastropathy
- ☐ Gastric vascular ectasia
- ☐ peptic ulceration

PREVIOUS

NEXT

**Important Note**

- Finishing test is mandatory, exit in the mid of the test will mark the student as absent.
- If you are uploading multiple files, first zip it.
- 01:06



192.168.6.2/Forms/Exan



Personal information

Student

Shahzeb
Hassan

Reg No

MB1924-1991

Scope

scope

Timer

01:37:37

Q#55

An 11 month old child who weighs 10 kg presents to you with 2 days history of loose stools and vomiting. Since this morning the child is unable take milk. On examination He is lethargic, has sunken eyes, skin pinch goes back very slowly. Which of the following regimes would you adopt to rehydrate this child?

- ☐ 300ml of IV fluids over 1 hour followed by 700ml of IV fluids over 5 hours.
- ☐ 400ml of IV fluids over 1 hour followed by 600ml of IV fluids over 5 hours
- ☐ 300ml of IV fluids over 30 minutes followed by 700ml of IV fluids over 2.5 hours
- ☐ Only give ORS after every loose stool
- ☐ 1000ml IV fluids over 1 hour

PREVIOUS

NEXT



Important Note

- Finishing test is mandatory, exit in the mid of the test will mark the student as absent.
- If you are uploading multiple files, first zip it.
- 01:26



192.168.6.2/Forms/Exan



Personal information

Student

Shahzeb
Hassan

Reg No

MB1924-1991

Scope

scope

Timer

01:34:27

Q#90

A 4 years old boy brought to the OPD with history of chronic diarrhea. On examination, patient is vitally stable, pale looking, with muscle wasting and protuberant abdomen. His weight and height falls below the 3rd centile for his age. He has rachitic findings and a bruise on the right leg. After investigation you diagnosed him as case of Celiac Disease and your started him on gluten free diet. What is the most common extra intestinal presentation / manifestation of this disease?

- ☐ Short Stature
- ☐ Vit D deficiency
- ☐ Anemia
- ☐ Clubbing
- ☐ Vit K deficiency

PREVIOUS

NEXT



Important Note

- Finishing test is mandatory, exit in the mid of the test will mark the student as absent.
- If you are uploading multiple files, first zip it.
- 01:26



192.168.6.2/Forms/Exan



Personal information

Student

Shahzeb
Hassan

Reg No

MB1924-1991

Scope

scope

Timer

01:39:11

Q#42

A 55-year-old man presents with worsening back pain, fever, and night sweats for the past month. He has no history of trauma. On examination, there is localized tenderness over the lower thoracic spine. MRI reveals vertebral body destruction with involvement of the adjacent intervertebral disc. Blood cultures are positive for *Staphylococcus aureus*. What is the most likely diagnosis?

- ☐ Disc herniation
- ☐ Epidural hematoma
- ☐ Osteomyelitis
- ☐ Spinal metastasis
- ☐ Spinal tuberculosis (Pott's disease)

PREVIOUS

NEXT



Important Note

- Finishing test is mandatory, exit in the mid of the test will mark the student as absent.
- If you are uploading multiple files, first zip it.
- 01:26

**Personal information****Student**Shahzeb
Hassan**Reg No**

MB1924-1991

Scope

scope

Timer

01:36:45

Q#62

A 6 years old female presented with complain of pain abdomen on/off. suddenly the patient started per rectal bleeding o/e there is a cystic swelling which is mobile in nature and about 7 x 7 cm in size. . ultrasound shows cystic lesion in ileocecal region. what is the most probable diagnosis?

- ☐ gut duplication cyst
- ☐ choledochal cyst
- ☒ duodenal stenosis
- ☐ ovarian cyst
- ☐ pancreatic pseudocyst

PREVIOUS

NEXT

Important Note

- Finishing test is mandatory, exit in the mid of the test will mark the student as absent.
- If you are uploading multiple files, first zip it.
- 01:26



192.168.6.2/Forms/Exan

**Personal information****Student**Shahzeb
Hassan**Reg No**

MB1924-1991

Scope

scope

Timer

01:39:19

Q#40

An 18-year-old man presented with severe headache, nuchal rigidity, and a fever. The patient was lethargic on examination with papilledema. He was started on broad spectrum antibiotics. Which of the following is the most appropriate step in his management?

- ☐ Lumbar puncture
- ☐ Brain MRI
- ☒ Intravenous steroids
- ☐ Hyperventilation and mannitol
- ☐ Blood culture & sensitivity

PREVIOUS

NEXT

**Important Note**

- Finishing test is mandatory, exit in the mid of the test will mark the student as absent.
- If you are uploading multiple files, first zip it.
- 01:26



192.168.6.2/Forms/Exan

**Personal information****Student**Shahzeb
Hassan**Reg No**

MB1924-1991

Scope

scope

Timer

01:36:24

Q#67

A 75 year old male presents with an acute ischemic stroke. On examination he has mild right arm and face weakness. He has spontaneous speech with occasional paraphasic errors. He can understand and follow commands. Repetition is severely impaired. Which of the following best explains his speech pattern?

- ☐ Broca's aphasia
- ☐ Transcortical aphasia
- ☐ Anomic aphasia
- ☐ Conductive aphasia
- ☐ Wernicke's aphasia

PREVIOUS

NEXT

**Important Note**

- Finishing test is mandatory, exit in the mid of the test will mark the student as absent.
- If you are uploading multiple files, first zip it.
- 01:26



192.168.6.2/Forms/Exan



Personal information

Student

Shahzeb
Hassan

Reg No

MB1924-1991

Scope

scope

Timer

01:36:40

Q#63

A 65-year-old laborer is brought to ER after he fell and had seizures working at a site on a hot summer afternoon. On examination his pulse is 120/m, Blood pressure is 100/70 mmHg, Temperature 105°F and Respiratory rate 28/m. His GCS is 12/15. His initial investigations show renal failure, hyperkalemia, severe metabolic acidosis, deranged liver profile and raised CPK. You suspect heat stroke. What are the two important features for diagnosis of heat stroke?

- ☐ Temperature >104°F and altered mental status
- ☒ Temperature >104°F and hyponatremia
- ☐ Temperature >102°F and altered mental status
- ☐ Temperature >102°F and altered mental status
- ☐ Temperature >104°F and renal failure

PREVIOUS

NEXT



Important Note

- Finishing test is mandatory, exit in the mid of the test will mark the student as absent.
- If you are uploading multiple files, first zip it.
- 01:26



192.168.6.2/Forms/Exan

**Personal information****Student**Shahzeb
Hassan**Reg No**

MB1924-1991

Scope

scope

Timer

01:35:45


Q#75

A 10 years old girl presented with distended abdomen, and jaundice for the last 1 month. she was operated for perforated gut at the age of 3 years at some local hospital and where during the procedure she was transfused blood as well. On examination, she is icteric, clubbed, shifting dullness +ve and splenomegaly. which of the following agents can not be the cause this condition?

- ☐ Hepatitis B Virus
- ☐ Hepatitis D Virus
- ☐ Hepatitis C Virus
- ☐ Hepatitis E Virus
- ☐ Hepatitis A Virus

PREVIOUS

NEXT

**Important Note**

- Finishing test is mandatory, exit in the mid of the test will mark the student as absent.
- If you are uploading multiple files, first zip it.
- 01:26



192.168.6.2/Forms/Exan



Personal information

Student

Shahzeb
Hassan

Reg No

MB1924-1991

Scope

scope

Timer

01:34:31

Q#89

Two days old female neonate presented with complain of absent anal opening and multiple associated anomalies. A diagnosis of anorectal malformation was made and work up was started for its management. His mother also told the doctor on duty that some meconium is coming through an opening below the vaginal opening. Which one of the following type of anomaly it is?

- ☐ A. RECTOVESTIBULAR FISTULA
- ☐ RECTOURETHERAL FISTULA
- ☒ C. IMPERFORATE ANUS WITHOUT FISTULA
- ☐ .UROGENITAL SINUS
- ☐ common cloaca

PREVIOUS

NEXT



Important Note

- Finishing test is mandatory, exit in the mid of the test will mark the student as absent.
- If you are uploading multiple files, first zip it.
- 01:26



192.168.6.2/Forms/Exan



Personal information

Student

Shahzeb
Hassan

Reg No

MB1924-1991

Scope

scope

Timer

01:35:33

Q#77

A 24-year-old nulliparous female with a history of recurrent deep vein thrombosis presents with shortness of breath. The full blood count and clotting screen reveals the following results: Hb 12.4 g/dl Plt 137 WBC $7.5 \times 10^9/l$ PT 14 secs APTT 46 secs What is the most likely underlying diagnosis?

- ☐ Third generation oral contraceptive pill use
- ☐ Protein C deficiency
- ☐ Antithrombin III deficiency .
- ☐ Antiphospholipid syndrome
- ☐ Activated protein C resistance

PREVIOUS

NEXT



Important Note

- Finishing test is mandatory, exit in the mid of the test will mark the student as absent.
- If you are uploading multiple files, first zip it.
- 01:26



192.168.6.2/Forms/Exan

**Personal information****Student**Shahzeb
Hassan**Reg No**

MB1924-1991

Scope

scope

Timer

01:35:07

Q#83

A 40-year-old presents to clinic with abnormal movements. He also complains of memory loss. On examination he has chorea. On further questioning he reveals that his father and grandfather had similar disease too. You suspect Huntington disease. What is the pathology in Huntington disease?

- ☐ Frameshift mutation
- ☐ Trinucleotide repeat
- ☐ Aneuploidy
- ☐ Polyploidy
- ☐ Polymorphism

PREVIOUS

NEXT

**Important Note**

- Finishing test is mandatory, exit in the mid of the test will mark the student as absent.
- If you are uploading multiple files, first zip it.
- 01:26



192.168.6.2/Forms/Exan



Personal information

Student

Shahzeb
Hassan

Reg No

MB1924-1991

Scope

scope

Timer

01:32:09

Q#112

A 58 yrs old presents to your clinic with dysphagia for solids for the past three months. He also complains of weight loss and loss of appetite. There is no other past medical history, apart from symptoms of indigestion and heart burn from the past 5 years. He regularly takes gaviscon. He is a heavy smoker. He undergo endoscopy which reveals a small tumor at the lower end of esophagus. What is the most likely cause for the tumor?

- ☐ Smoking
- ☒ Barrett's esophagus
- ☐ H pylori
- ☐ Esophageal candidiasis
- ☐ Esophageal pouch

PREVIOUS

NEXT

Important Note

- Finishing test is mandatory, exit in the mid of the test will mark the student as absent.
- If you are uploading multiple files, first zip it.
- 01:26



192.168.6.2/Forms/Exan

**Personal information****Student**Shahzeb
Hassan**Reg No**

MB1924-1991

Scope

scope

Timer

01:34:13

Q#93

A 50-year-old woman with diabetes awakens with right body weakness. Examination indicates relatively symmetrical upper motor neuron pattern of weakness involving the face, arm, and leg. There are no sensory abnormalities. Language is preserved. A stroke associated with this presentation is most likely with damage to which of the following?

- ☐ Internal capsule
- ☐ Cerebellum
- ☐ Putamen
- ☐ Caudate
- ☐ Amygdala

PREVIOUS

NEXT

**Important Note**

- Finishing test is mandatory, exit in the mid of the test will mark the student as absent.
- If you are uploading multiple files, first zip it.
- 01:26



192.168.6.2/Forms/Exan



Personal information

Student

Shahzeb
Hassan

Reg No

MB1924-1991

Scope

scope

Timer

01:34:23

Q#91

You are called to see a 44 year old male politician, admitted to the medical ward. Medical team was made aware by the family that he had been using Heroin since the last few years. This was also evident in his urine drug screen. He has been exhibiting signs of withdrawals and has been sweating profusely. When you see him, he admits to this and states that he has been using around Rs 2000/3000 worth of heroin daily, since the last 5 years. He was initially smoking it, but has recently resorted to injecting it in his groin. He has tried multiple times to come of it unsuccessfully. He feels ashamed and does not want this use to get out of hand, effecting his personal life and career. How will you manage him best?

- ☐ Assess his withdrawals and treat symptomatically
- ☐ Assess his withdrawals and give him intensive psychotherapy
- ☐ Assess his withdrawals, prescribe him medications and involve a psychologist
- ☐ Assess his withdrawals and provide information about local and national drug rehabilitation agencies
- ☐ Assess his withdrawals and provide information about the harmful effects of his illicit drug use

PREVIOUS

NEXT



Important Note

- Finishing test is mandatory, exit in the mid of the test will mark the student as absent.
- If you are uploading multiple files, first zip it.
- 01:26



192.168.6.2/Forms/Exan

**Personal information****Student**Shahzeb
Hassan**Reg No**

MB1924-1991

Scope

scope

Timer

01:36:11

Q#70

A 76 year old man with hypertension and diabetes complained of a severe headache. On arrival to the emergency department, he was stuporous, weak on the right side, and aphasic. Which of the following is the most appropriate step in the evaluation of this patient?

- ☐ CT brain
- ☐ MRI brain
- ☐ Magnetic resonance angiography
- ☐ Digital subtraction angiogram
- ☐ Spinal tap and blood cultures

PREVIOUS

NEXT

**Important Note**

- Finishing test is mandatory, exit in the mid of the test will mark the student as absent.
- If you are uploading multiple files, first zip it.
- 01:26

**Personal information****Student**Shahzeb
Hassan**Reg No**

MB1924-1991

Scope

scope

Timer

01:33:34

Q#98

A 9 years old male presented with 2 days history of fever and abdominal pain. He belongs from the flood affected area. Past history is not significant. on Examination, he is febrile of 101°F , has icteric sclera and there is soft hepatomegaly. what test would most likely confirm his diagnosis?

- ☐ Hepatitis A Serology (HAV IgM)
- ☐ Hepatitis B serology (HbcAg)
- ☐ 24 hour copper excretion
- ☐ Ultrasound Abdomen
- ☐ paracetamol levels in blood

PREVIOUS

NEXT

**Important Note**

- Finishing test is mandatory, exit in the mid of the test will mark the student as absent.
- If you are uploading multiple files, first zip it.
- 01:26



192.168.6.2/Forms/Exan

**Personal information****Student**Shahzeb
Hassan**Reg No**

MB1924-1991

Scope

scope

Timer

01:36:19

Q#68

A 25 year old female presents with episodes of confusion. These episodes start with a rising feeling in her abdomen followed by anxiety and diaphoresis. Her family states she will mumble and hold her left arm stiff while her right arm picks at her shirt. These episodes will last for 45 seconds before resolving. She is tired and confused after these episodes have occurred. Which of the following is the most likely localization for her symptoms?

- ☐ Left orbitofrontal lobe
- ☐ Left lateral temporal lobe
- ☐ Right occipital lobe
- ☐ Right mesial temporal lobe
- ☐ Right dorsolateral frontal lobe

PREVIOUS

NEXT

**Important Note**

- Finishing test is mandatory, exit in the mid of the test will mark the student as absent.
- If you are uploading multiple files, first zip it.
- 01:26



192.168.6.2/Forms/Exan

**Personal information****Student**Shahzeb
Hassan**Reg No**

MB1924-1991

Scope

scope

Timer

01:36:33

Q#65

A 5 years old boy presented with history of high grade fever, headache and vomiting from last 2 days. The mother also reports an episode of fits at home. On examination there is neck stiffness and positive kernig's and brudzinski's sign. What is the most probable diagnosis:

- ☐ Brain tumor
- ☐ Meningitis
- ☐ Migraine
- ☐ Cyclic vomiting syndrome
- ☐ Tension headache

PREVIOUS

NEXT

**Important Note**

- Finishing test is mandatory, exit in the mid of the test will mark the student as absent.
- If you are uploading multiple files, first zip it.
- 01:26



192.168.6.2/Forms/Exan

**Personal information****Student**Shahzeb
Hassan**Reg No**

MB1924-1991

Scope

scope

Timer

01:36:02


Q#72

A 32-year-old lady comes to the ER with fever, abdominal pain and vomiting. On examination, she had mild jaundice and tender right upper quadrant. The patient says her son had been infected with hepatitis A virus a week ago. What is the appropriate test to diagnose her current status?

- ☐ ALT
- ☐ Anti HAV IgG
- ☐ Anti HAV IgM
- ☐ PT/INR
- ☐ Ultrasound abdomen

PREVIOUS

NEXT

**Important Note**

- Finishing test is mandatory, exit in the mid of the test will mark the student as absent.
- If you are uploading multiple files, first zip it.
- 01:26

**Personal information****Student**Shahzeb
Hassan**Reg No**

MB1924-1991

Scope

scope

Timer

01:36:07

Q#71

36 years old female presented with cold extremities , Low B.P and is drowsy since yesterday, On examination , she is Obese and looking pale ,having dry skin with coarse thin hair. What is the most probable cause of her Hypothermia?

- ☐ Sepsis
- ☐ Cardiogenic Shock
- ☐ Hypothyroidism
- ☐ Stroke
- ☐ None of the above

PREVIOUS

NEXT

**Important Note**

- Finishing test is mandatory, exit in the mid of the test will mark the student as absent.
- If you are uploading multiple files, first zip it.
- 01:26

**Personal information****Student**Shahzeb
Hassan**Reg No**

MB1924-1991

Scope

scope

Timer

01:35:25

Q#79

A PG patient came to antenatal OPD with 15 weeks gestation, patient is confused, semi drowsy condition, not oriented to time and place. According to her husband she was having severe vomiting and diarrhoea 2 days back. On investigations HB is 10gm/dl, tlc 10,000. On urine R/E pus cells 2-4, sugar nil, ketones +++. On examination B/P 100/65mmHg, pulse 110/min, patient is pale and dehydrated. What is the diagnosis of this patient?

- ☐ Wernicke's encephalopathy
- ☐ Eclampsia
- ☐ Gastroenteritis
- ☐ Food poisoning
- ☐ Anxiety

PREVIOUS

NEXT

**Important Note**

- Finishing test is mandatory, exit in the mid of the test will mark the student as absent.
- If you are uploading multiple files, first zip it.
- 01:26



192.168.6.2/Forms/Exan

**Personal information****Student**Shahzeb
Hassan**Reg No**

MB1924-1991

Scope

scope

Timer

01:39:00

Q#44

25 years Old Male, Tall and Thin Build, Disproportionately Long Arms, Legs and Kyphoscoliosis presented to His Physician with decreased vision, He was having His Echo report in His hand which was done 2 weeks back and it showed Mitral Valve Prolapse and Dilatation Of Ascending Aorta. Given His Underlying Condition what will be most affected ?

- ☐ height of the body
- ☐ heart, eyes, blood vessels and bones
- ☐ spine and weight
- ☐ learning ability
- ☐ skin changes

PREVIOUS

NEXT

**Important Note**

- Finishing test is mandatory, exit in the mid of the test will mark the student as absent.
- If you are uploading multiple files, first zip it.
- 01:26



192.168.6.2/Forms/Exan

**Personal information****Student**Shahzeb
Hassan**Reg No**

MB1924-1991

Scope

scope

Timer

01:37:11

Q#57

A young 30-year-old male with history of polycystic kidney disease presented with altered sensorium and severe headache for the last one day. On examination his blood pressure was 170/100mmHg with a GCS of 14/15. There was no focal weakness associated. Rest of the lab investigation were reported to be normal. What can be the first line (most appropriate) investigation?

- ☐ MRI Brain
- ☐ Cerebral angiography
- ☐ CSF R/E
- ☐ CT Venogram
- ☐ CT Brain plain

PREVIOUS

NEXT

**Important Note**

- Finishing test is mandatory, exit in the mid of the test will mark the student as absent.
- If you are uploading multiple files, first zip it.
- 01:26



192.168.6.2/Forms/Exan

**Personal information****Student**Shahzeb
Hassan**Reg No**

MB1924-1991

Scope

scope

Timer

01:39:15

Q#41

A 30 days old male presented with c/o jaundice since birth and passing clay colored stool. he is also failure to thrive and having abdominal distention.usg done showing poor visualiazation of gall bladder even after post feed also. what is your diagnosis?

- ☐ ... choledochal cyst
- ☐ billiarey atresia
- ☐ alpha 1 antitrypsin deficiency
- ☐ Wilson disease
- ☐ physiological jaundice

PREVIOUS

NEXT

**Important Note**

- Finishing test is mandatory, exit in the mid of the test will mark the student as absent.
- If you are uploading multiple files, first zip it.
- 01:26



192.168.6.2/Forms/Exan

**Personal information****Student**Shahzeb
Hassan**Reg No**

MB1924-1991

Scope

scope

Timer

01:44:33

Q#28

A 2 years old unvaccinated boy presented with history of low grade fever, headache and vomiting. He also has past history of cough ,loosing weight and pallor. The mother also reported an episode of fit at home. On examination there is neck stiffness and positive kernig's sign. Lumber puncture is done and CSF examination shows Cell count 400 (Polys 15% and Lymphos 85%),Protein 500 mg/dL and glucose 15 mg/dL. CT scan reported non communicating Hydrocephalus. The most probable diagnosis is

- ☐ Bacterial Meningitis
- ☐ Congenital Hydrocephalus
- ☐ Intracranial Tumor
- ☐ Tuberculous Meningitis
- ☐ Viral Encephalitis

PREVIOUS

NEXT

**Important Note**

- Finishing test is mandatory, exit in the mid of the test will mark the student as absent.
- If you are uploading multiple files, first zip it.
- 01:16



192.168.6.2/Forms/Exan

**Personal information****Student**Shahzeb
Hassan**Reg No**

MB1924-1991

Scope

scope

Timer

01:36:50

Q#61

A 60-year-old man diabetic and hypertensive presented to the ER with sudden onset left sided weakness and aphasia for the last 6 hours. On examination he has a blood pressure of 200/120mmHg, pulse was 60. Power on the left side in the upper and lower limbs was 2/5 and planter on the left side was up-going. What can be the most appropriate management step?

- ☐ Aspirin therapy
- ☐ MRI Brain
- ☐ CT-Brain
- ☐ Alteplase
- ☐ Thrombectomy

PREVIOUS

NEXT

**Important Note**

- Finishing test is mandatory, exit in the mid of the test will mark the student as absent.
- If you are uploading multiple files, first zip it.
- 01:26



192.168.6.2/Forms/Exan

**Personal information****Student**Shahzeb
Hassan**Reg No**

MB1924-1991

Scope

scope

Timer

01:44:10

Q#29

A 70-year-old male known hypertensive and having heart failure was standing in a long queue on a hot summer day when he collapsed and was taken to ER. In ER his pulse is 140/m, Blood pressure is 100/70 mmHg, Temperature 104°F and Respiratory rate 28/m. He is confused and has ataxia. His ECG and Echo have no new changes. His investigations show rhabdomyolysis and renal failure. Which of the following is an early sign of heat stroke?

- ☐ Seizures
- ☐ Ataxia
- ☐ Lower limb weakness
- ☐ Aphasia
- ☐ Asterognosis

PREVIOUS

NEXT

**Important Note**

- Finishing test is mandatory, exit in the mid of the test will mark the student as absent.
- If you are uploading multiple files, first zip it.
- 01:16

**Personal information****Student**Shahzeb
Hassan**Reg No**

MB1924-1991

Scope

scope

Timer

01:38:40

Q#47

The highest risk of development of coronary artery aneurysms in Kawasaki disease is in

- ☐ Acute phase
- ☐ Convulsant phase
- ☐ Subacute phase
- ☐ Paroxysmal phase
- ☐ Catarrhal phase

PREVIOUS

NEXT

**Important Note**

- Finishing test is mandatory, exit in the mid of the test will mark the student as absent.
- If you are uploading multiple files, first zip it.
- 01:26



192.168.6.2/Forms/Exan

**Personal information****Student**Shahzeb
Hassan**Reg No**

MB1924-1991

Scope

scope

Timer

01:41:39

Q#34

A 3 years old patient was seen in OPD with history of having frequent falls, he was unable to maintain his balance on standing position. You are asked by your senior doctor to do check for cerebellar functions. Which of the following one test is part of the cerebellar function test?

- ☐ Tunning fork test
- ☐ Heel shin test
- ☐ Pupillary reflexes test
- ☐ Knee jerk test
- ☐ Plantar test

PREVIOUS

NEXT

**Important Note**

- Finishing test is mandatory, exit in the mid of the test will mark the student as absent.
- If you are uploading multiple files, first zip it.
- 01:16



192.168.6.2/Forms/Exan

**Personal information****Student**Shahzeb
Hassan**Reg No**

MB1924-1991

Scope

scope

Timer

01:39:37

Q#39**What will be the initial Drug combination for empirical treatment for bacterial meningitis?**

- ☐ Vancomycin and Ceftriaxone
- ☐ Ceftriaxone and meropenem
- ☐ Vancomycin plus Ceftriaxone
- ☐ Meropenem and penicillin
- ☐ Penicillin and Ceftriaxone

PREVIOUS

NEXT

**Important Note**

- Finishing test is mandatory, exit in the mid of the test will mark the student as absent.
- If you are uploading multiple files, first zip it.
- 01:26



192.168.6.2/Forms/Exan



Personal information

Student

Shahzeb
Hassan

Reg No

MB1924-1991

Scope

scope

Timer

01:36:36

Q#64

A twenty-five-year-old male having a history of laparotomy for gut ischemia secondary to internal volvulus for which extensive small gut resection was performed resulted in high output stoma of jejunum, presented to the ED with severe dehydration and nutritional impairment. What would be the appropriate way of nutritional rehabilitation of this patient?

- ☐ Only micronutrient supplementation
- ☐ Feeding jejunostomy
- ☒ Parenteral nutrition
- ☐ Enteral nutrition with Nasogastric tube
- ☐ Feeding with elementary diets

PREVIOUS

NEXT



Important Note

- Finishing test is mandatory, exit in the mid of the test will mark the student as absent.
- If you are uploading multiple files, first zip it.
- 01:26



192.168.6.2/Forms/Exan



Personal information

Student

Shahzeb
Hassan

Reg No

MB1924-1991

Scope

scope

Timer

01:39:07

Q#43

A 7 years old female presented with abdominal pain, burning micturition and a cystic swelling in hypogastric region from last 7 days. o/e there is a swelling of about 7x7 cm in hypogastric region. usg is done showing some cystic lesion containing pus of about 40 ml communicating with the anterior abdominal wall. communication with bladder can not be ruled out. what is your provisional diagnosis?

- ☐ patent vitellointestinal duct
- ☐ bladder abscess
- ☒ bladder carcinoma
- ☐ infected urachal cyst
- ☐ duplication cyst

PREVIOUS

NEXT



Important Note

- Finishing test is mandatory, exit in the mid of the test will mark the student as absent.
- If you are uploading multiple files, first zip it.
- 01:26



192.168.6.2/Forms/Exan



Personal information

Student

Shahzeb
Hassan

Reg No

MB1924-1991

Scope

scope

Timer

01:39:26

Q#40

An 18-year-old man presented with severe headache, nuchal rigidity, and a fever. The patient was lethargic on examination with papilledema. He was started on broad spectrum antibiotics. Which of the following is the most appropriate step in his management?

- ☐ Lumbar puncture
- ☐ Brain MRI
- ☐ Intravenous steroids
- ☐ Hyperventilation and mannitol
- ☐ Blood culture & sensitivity

PREVIOUS

NEXT



Important Note

- Finishing test is mandatory, exit in the mid of the test will mark the student as absent.
- If you are uploading multiple files, first zip it.
- 01:26



192.168.6.2/Forms/Exan



Personal information

Student

Shahzeb
Hassan

Reg No

MB1924-1991

Scope

scope

Timer

01:42:14

Q#33

A 55-year-old man presents to the emergency department due to coughing up blood in the morning. His symptoms are accompanied by fever, arthralgia affecting the wrists and knees, and unintentional weight loss over the course of 3 months prior to presentation. The patient also noticed mild shortness of breath. On physical exam, there is mild nasal crusting and bloody nasal discharge. There are no lesions in the mouth. There is tenderness to palpation of the wrist and knees. Laboratory testing is significant for an elevated erythrocyte sedimentation rate, C-reactive protein, and a creatinine of 2.5 mg/dL (his creatinine is normally 0.9 mg/dL). A radio graph of the chest demonstrates pulmonary nodules. What is the most Likely Diagnosis?

- ☐ Churg-Strauss Syndrome
- ☐ Pulmonary T.B
- ☐ Granulomatosis with Polyangitis(Wegener's)
- ☐ Good Pastures syndrome
- ☐ IgA Nephropathy

PREVIOUS

NEXT

Important Note

- Finishing test is mandatory, exit in the mid of the test will mark the student as absent.
- If you are uploading multiple files, first zip it.
- 01:16

**Personal information**

Student

Shahzeb
Hassan

Reg No

MB1924-1991

Scope

scope

Timer

01:46:45

Q#22

A 13-year-old boy gets admitted with jaundice for the last one month and fits for the last three days. On physical examination, he has a blood pressure 110/60 mm Hg, heart rate 86 per min, afebrile, scleral icterus present and abdomen is firm. Labs reveal raised total bilirubin, ALT and deranged INR. The mother also gives the history of two elder siblings who died due to the same condition. What will be the most appropriate step in the management of this patient?

- ☐ Interferon
- ☐ Penicillamine
- ☐ Ribavirin
- ☐ Venesection
- ☐ Zinc supplementation

PREVIOUS

NEXT

**Important Note**

- Finishing test is mandatory, exit in the mid of the test will mark the student as absent.
- If you are uploading multiple files, first zip it.
- 01:16

**Personal information****Student**Shahzeb
Hassan**Reg No**

MB1924-1991

Scope

scope

Timer

01:41:17

Q#35

A 42- year- old man presents with ptosis on the left eyelid, numbness of his left face, right arm and leg. Associated h/o vomiting, vertigo, diplopia, speech disturbance, swallowing difficulty and falling to the left side. Occlusion of which artery is most likely responsible?

- ☐ Vertebral artery
- ☐ Anterior inferior cerebellar artery
- ☐ Superior cerebellar artery
- ☐ Posterior cerebral artery
- ☐ Anterior Cerebral artery

PREVIOUS

NEXT

**Important Note**

- Finishing test is mandatory, exit in the mid of the test will mark the student as absent.
- If you are uploading multiple files, first zip it.
- 01:16



192.168.6.2/Forms/Exan

**Personal information****Student**Shahzeb
Hassan**Reg No**

MB1924-1991

Scope

scope

Timer

01:37:33

Q#56

A 3 years old patient comes to you with sudden onset of loss of balance and tremors since waking up this morning. He slept well last night and has no fever. Mother suffers from depression. What could be the possible likely diagnosis?

- ☐ Meningitis
- ☐ High blood pressure
- ☐ Acute vitamin deficiency
- ☐ Drug intoxication
- ☐ Head Injury

PREVIOUS

NEXT

**Important Note**

- Finishing test is mandatory, exit in the mid of the test will mark the student as absent.
- If you are uploading multiple files, first zip it.
- 01:26

**Personal information****Student**Shahzeb
Hassan**Reg No**

MB1924-1991

Scope

scope

Timer

01:46:18

Q#23

Which is the SINGLE MOST likely drug to be associated with medication-overuse headache (MOH)? Select ONE option only.

- ☐ Ibuprofen
- ☐ sodium valproate
- ☐ amoxicillin
- ☐ duloxetine
- ☐ Pregabalin

PREVIOUS

NEXT

**Important Note**

- Finishing test is mandatory, exit in the mid of the test will mark the student as absent.
- If you are uploading multiple files, first zip it.
- 01:16

**Personal information****Student**Shahzeb
Hassan**Reg No**

MB1924-1991

Scope

scope

Timer

01:38:03

Q#51

A 65-year-old lady with a history of aspirin induced gastritis has now presented with severe hip and knee joint pain that is thought to be due to osteoarthritis. She now requires treatment with NSAIDS. Which of the following would be most helpful for the prophylaxis against recurrent GI bleeding?

- ☐ Omeprazole
- ☐ Sucralfate
- ☐ Nizatidine
- ☐ Atropine
- ☐ misoprostol

PREVIOUS

NEXT

**Important Note**

- Finishing test is mandatory, exit in the mid of the test will mark the student as absent.
- If you are uploading multiple files, first zip it.
- 01:26

**Personal information****Student**Shahzeb
Hassan**Reg No**

MB1924-1991

Scope

scope

Timer

01:40:35

Q#36

A 45-year-old male patient presented with two episodes of hematemesis. On examination he is having signs of chronic liver disease. Regarding upper GI bleed which of the following is associated with reduced mortality and morbidity?

- ☐ Proton pump inhibitors
- ☐ Antacid
- ☐ Antibiotics
- ☐ Decadron
- ☐ Normal saline

PREVIOUS

NEXT

**Important Note**

- Finishing test is mandatory, exit in the mid of the test will mark the student as absent.
- If you are uploading multiple files, first zip it.
- 01:16



192.168.6.2/Forms/Exan

**Personal information****Student**Shahzeb
Hassan**Reg No**

MB1924-1991

Scope

scope

Timer

01:42:45

Q#32

A 30-year-old man presents to the emergency department after a motorbike accident. He complains of severe back pain and inability to move his legs. On examination, he has loss of sensation below the umbilicus (T10 level) and absent motor function in both lower limbs. Reflexes are absent in the lower limbs, and rectal tone is diminished. MRI reveals a fracture at T12 with spinal cord compression. Which of the following is the next best step in management?

- ☐ Administer high-dose corticosteroids
- ☐ Immediate surgical decompression and stabilization
- ☐ Initiate physiotherapy and rehabilitation
- ☐ Observe and repeat imaging in 48 hours
- ☐ Start anticoagulation to prevent deep vein thrombosis

PREVIOUS

NEXT

**Important Note**

- Finishing test is mandatory, exit in the mid of the test will mark the student as absent.
- If you are uploading multiple files, first zip it.
- 01:16



192.168.6.2/Forms/Exan



Personal information

Student

Shahzeb
Hassan

Reg No

MB1924-1991

Scope

scope

Timer

01:38:14


Q#50

A 30-year-old woman presented with bilateral asynchronous, violent ballistic movements of her arms and legs. The patient was conscious during these events but can not communicate with surroundings. Each episode lasted between 60 and 180 seconds Which of the following tests is most likely to reveal the diagnosis?

- ☐ Routine EEG
- ☐ Video monitoring EEG
- ☐ MRI of the brain
- ☐ MR Spectroscopy brain
- ☐ Serum Prolactin level

PREVIOUS

NEXT



Important Note

- Finishing test is mandatory, exit in the mid of the test will mark the student as absent.
- If you are uploading multiple files, first zip it.
- 01:26



192.168.6.2/Forms/Exan



Personal information

Student

Shahzeb
Hassan

Reg No

MB1924-1991

Scope

scope

Timer

01:43:22

Q#30

A 60- year- old man presents with recent onset of right facial weakness. He can not lift his right eyebrow or close his right eye. He has a depressed right nasolabial fold. He also reports decreased taste sensation. What is the best treatment?

- ☐ Aspirin
- ☐ Heparin
- ☐ Prednisone
- ☐ Intravenous recombinant tissue plasminogen activator (rtPA) if he presents within 4.5 hours of symptom onset.
- ☐ Clopidogrel

PREVIOUS

NEXT



Important Note

- Finishing test is mandatory, exit in the mid of the test will mark the student as absent.
- If you are uploading multiple files, first zip it.
- 01:16



192.168.6.2/Forms/Exan



Personal information

Student

Shahzeb
Hassan

Reg No

MB1924-1991

Scope

scope

Timer

01:37:02

Q#59

A 44 year old lady comes to the office because of a 1-month history of worsening right upper quadrant abdominal pain and discomfort. She describes the pain as a dull ache and says it is not affected by eating or defecating. Vital signs are normal. Abdominal examination discloses hepatomegaly. Results of liver function tests are within the reference ranges. Serologic studies is positive for Hepatitis C. Ultrasonography of the abdomen shows a 4×4-cm mass in the right lobe of the liver. Which of the following is the most likely diagnosis?

- ☐ Hepatic adenoma
- ☐ Hepatocellular cancer
- ☐ Hydatid cyst
- ☐ Liver abscess
- ☐ Metastatic ovarian cancer

PREVIOUS

NEXT



Important Note

- Finishing test is mandatory, exit in the mid of the test will mark the student as absent.
- If you are uploading multiple files, first zip it.
- 01:26



Personal information

Student

Shahzeb
Hassan

Reg No

MB1924-1991

Scope

scope

Timer

01:37:46

Q#53

A 2-year-old boy is brought into the emergency room with a complaint of fever for 6 days and the development of a limp. On examination, he is found to have an erythematous macular exanthem over his body as shown in image A, conjunctivitis, dry and cracked lips, a red throat, and cervical lymphadenopathy. There is a grade 2/6 vibratory systolic ejection murmur at the lower left sternal border. A white blood cell (WBC) count and differential show predominant neutrophils with increased platelets on smear. Later, he develops the findings as seen in image B. Which of the following is the most likely diagnosis?

- ☐ Scarlet fever
- ☐ Rheumatic fever
- ☐ Kawasaki disease
- ☐ JIA
- ☐ Infectious mononucleosis

PREVIOUS

NEXT



Important Note

- Finishing test is mandatory, exit in the mid of the test will mark the student as absent.
- If you are uploading multiple files, first zip it.
- 01:26



192.168.6.2/Forms/Exan



Personal information

Student

Shahzeb
Hassan

Reg No

MB1924-1991

Scope

scope

Timer

01:45:09

Q#26

A 50-year-old farmer is brought to ER with nausea, vomiting, diarrhea and confusion. On examination he is profusely sweating, his pulse is 40/m and BP is 95/70 mmHg and Oxygen sats are 88% on room air. His pupils are pinpoint. On auscultation he has wheezes in chest. What is the first medication you would administer?

- ☐ Pralidoxime
- ☐ Atropine
- ☐ Flumazenil
- ☐ Naloxone
- ☐ Sodium bicarbonate

PREVIOUS

NEXT



Important Note

- Finishing test is mandatory, exit in the mid of the test will mark the student as absent.
- If you are uploading multiple files, first zip it.
- 01:16



192.168.6.2/Forms/Exan

**Personal information****Student**Shahzeb
Hassan**Reg No**

MB1924-1991

Scope

scope

Timer

01:38:46

Q#46

A 2 year old child presented with hx of vomiting and watery diarrhea for the last 2 days . He is bottle fed and also taking solid diet . On examination he is active , alert with no signs of dehydration. What is the common cause of diarrhea in children

- ☐ E.Coli
- ☐ Shigella
- ☐ Rota virus
- ☐ Adenovirus
- ☐ Norwalk virus

PREVIOUS

NEXT

**Important Note**

- Finishing test is mandatory, exit in the mid of the test will mark the student as absent.
- If you are uploading multiple files, first zip it.
- 01:26

**Personal information**

Student

Shahzeb
Hassan

Reg No

MB1924-1991

Scope

scope

Timer

01:38:32

Q#48

A 1 year old child presented with complains of abdominal distention on/off and constipation since birth. According to the parents, patient passes stool after 5 to 7 days with enemas after which the abdominal distention settles. On examination, the anal opening is normal with no anal fissures around. On PR there is gush of stool coming out. Parents also told that patient passed meconium after 3rd day of life. There is no history of lethargy and patient is failure to thrive also. Based on history and examination what is your provisional diagnosis?

- ☐ functional constipation
- ☐ hirschsprung disease
- ☐ hypothyroidism
- ☐ ectopic anus
- ☐ inflammatory bowel disease

PREVIOUS

NEXT

**Important Note**

- Finishing test is mandatory, exit in the mid of the test will mark the student as absent.
- If you are uploading multiple files, first zip it.
- 01:26



192.168.6.2/Forms/Exan



Personal information

Student

Shahzeb
Hassan

Reg No

MB1924-1991

Scope

scope

Timer

01:37:42

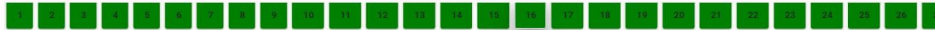Q#54

A 25 years old male having a history of laparotomy for gut ischemia secondary to internal volvulus for which extensive small gut resection was performed resulted in high output stoma of jejunum, presented to the ED with severe dehydration and nutritional impairment. What would be the appropriate way of nutritional rehabilitation of this patient?

- ☐ Enteral nutrition with Nasogastric tube
- ☐ Feeding jejunostomy
- ☐ Parenteral nutrition
- ☐ Feeding with elementary diets
- ☐ Only micronutrient supplementation

PREVIOUS

NEXT



Important Note

- Finishing test is mandatory, exit in the mid of the test will mark the student as absent.
- If you are uploading multiple files, first zip it.
- 01:26

**Personal information****Student**Shahzeb
Hassan**Reg No**

MB1924-1991

Scope

scope

Timer

01:44:51

Q#27

An 8 days old baby boy born at 30 weeks of gestation developed abdominal distention,vomiting and not tolerating his nasogastric formula feeds. An X-ray abdomen was done which revealed presence of gas in walls of small and large intestine (pneumatosis intestinalis). What is the most likely diagnosis in this baby?

- ☐ Acute gastroenteritis
- ☐ Necrotizing enterocolitis
- ☐ Pyloric stenosis
- ☐ Tracheoesophageal fistula
- ☐ Worm infestation

PREVIOUS

NEXT

**Important Note**

- Finishing test is mandatory, exit in the mid of the test will mark the student as absent.
- If you are uploading multiple files, first zip it.
- 01:16



192.168.6.2/Forms/Exan

**Personal information****Student**Shahzeb
Hassan**Reg No**

MB1924-1991

Scope

scope

Timer

01:45:35

Q#25

A male neonate immediately after birth was brought by his parents to the emergency department with complains of absent anal opening. After initial evaluation, the doctor on duty advised some necessary resuscitative measures and a plan of investigation was given. A prone cross table lateral view x ray abdomen was also advised. What is the ideal time at which this x-ray should be done?

- ☐ immediately after birth
- ☐ 12 hours of life
- ☐ 24 hours of life
- ☐ 48 hours of life
- ☐ no need of xray

PREVIOUS

NEXT

**Important Note**

- Finishing test is mandatory, exit in the mid of the test will mark the student as absent.
- If you are uploading multiple files, first zip it.
- 01:16



192.168.6.2/Forms/Exan

**Personal information****Student**Shahzeb
Hassan**Reg No**

MB1924-1991

Scope

scope

Timer

01:38:22

Q#49

A previously well 5 years old girl presents to OPD with 2 days history of fever and vomiting. There is no history of head trauma or any documented weight loss. On examination patient is having temperature of 104° F and neck stiffness is positive. What can be the most likely diagnosis?

- ☐ Migraine
- ☐ Brain tumor
- ☐ Brain hemorrhage
- ☐ Meningitis
- ☐ Sepsis

PREVIOUS

NEXT

**Important Note**

- Finishing test is mandatory, exit in the mid of the test will mark the student as absent.
- If you are uploading multiple files, first zip it.
- 01:26

**Personal information****Student**Shahzeb
Hassan**Reg No**

MB1924-1991

Scope

scope

Timer

01:37:53

Q#52

A 11 year old boy was brought in by his mother for abnormal movements. On examination he repeatedly wiped his nose and cleared his throat. He was able to suppress these movements when asked but only temporarily. Which of the following terms best describes these movements?

- ☐ Stereotypy
- ☐ Ballism
- ☐ Tics
- ☐ Akathisia
- ☐ Myoclonus

PREVIOUS

NEXT

**Important Note**

- Finishing test is mandatory, exit in the mid of the test will mark the student as absent.
- If you are uploading multiple files, first zip it.
- 01:26



192.168.6.2/Forms/Exan



Personal information

Student

Shahzeb
Hassan

Reg No

MB1924-1991

Scope

scope

Timer

01:38:51

Q#45

A 35 year old mountaineer is climbing K2 mountain when he develops severe shortness of breath, chest tightness, persistent cough, and frothy pink sputum. On examination he is tachycardiac with respiratory rate of 45/m and Oxygen saturations of 85%. What is the first step in management of this patient?

- ☐ Steroids
- ☐ Acetazolamide
- ☐ Oxygen
- ☐ Furosamide
- ☐ Descent to lower altitude

PREVIOUS

NEXT



Important Note

- Finishing test is mandatory, exit in the mid of the test will mark the student as absent.
- If you are uploading multiple files, first zip it.
- 01:26

**Personal information****Student**Shahzeb
Hassan**Reg No**

MB1924-1991

Scope

scope

Timer

01:36:56

Q#60

A 22-year-old male is brought to the emergency department after being struck on the head during a fight. He was initially alert but became drowsy over the next hour. Examination reveals anisocoria (right pupil dilated), a GCS score of 10, and left-sided weakness. A CT scan shows a biconvex hyperdense lesion in the right temporal region. What is the most likely diagnosis?

- ☐ Acute subdural hematoma
- ☐ Brain contusion
- ☐ Epidural hematoma
- ☐ Intracerebral hemorrhage
- ☐ Subarachnoid hemorrhage

PREVIOUS

NEXT

**Important Note**

- Finishing test is mandatory, exit in the mid of the test will mark the student as absent.
- If you are uploading multiple files, first zip it.
- 01:26



192.168.6.2/Forms/Exan

**Personal information****Student**Shahzeb
Hassan**Reg No**

MB1924-1991

Scope

scope

Timer

01:39:57

Q#37

1 year old vaccinated child brought to OPD with history of recurrent loose motion for the last 4 months. There is no history of fever and vomiting and no blood in stools. Weaning was started at the age of 6 months with wheat cerelac. There is no TB contact. On examination the patient is wasted, pale and has distended abdomen. What is the most likely diagnosis.

- ☐ Intestinal TB
- ☐ Celiac Disease
- ☐ Intussusception
- ☐ Inflammatory bowel disease
- ☐ Gastroenteritis

PREVIOUS

NEXT

**Important Note**

- Finishing test is mandatory, exit in the mid of the test will mark the student as absent.
- If you are uploading multiple files, first zip it.
- 01:26



192.168.6.2/Forms/Exan



Personal information

Student

Shahzeb
Hassan

Reg No

MB1924-1991

Scope

scope

Timer

01:37:06

Q#58

A 30 year old woman presented with bilateral, asynchronous ballistic movements of her arms and legs. The patient was conscious during these events, often saying that she felt like she was being attacked. Each episode lasted between 30 and 120 seconds Which of the following tests is most likely to reveal the diagnosis?

- ☐ Routine EEG
- ☐ Video EEG
- ☐ MRI of the brain
- ☐ MR Spectroscopy
- ☐ Prolactin level

PREVIOUS

NEXT



Important Note

- Finishing test is mandatory, exit in the mid of the test will mark the student as absent.
- If you are uploading multiple files, first zip it.
- 01:26



192.168.6.2/Forms/Exan

**Personal information****Student**Shahzeb
Hassan**Reg No**

MB1924-1991

Scope

scope

Timer

01:45:53

Q#24

A 32-year-old lady presents to clinic with flank pain and decreased urine quantity. She also feels nauseated and has lost her appetite. Further investigations show deranged renal functions and large cystic kidneys on ultrasound. You diagnose her with adult polycystic kidney disease. What is the mode of inheritance of this disease?

- ☐ Autosomal recessive
- ☐ Autosomal dominant
- ☐ X-linked
- ☐ Polymorphism
- ☐ Aneuploidy

PREVIOUS

NEXT

**Important Note**

- Finishing test is mandatory, exit in the mid of the test will mark the student as absent.
- If you are uploading multiple files, first zip it.
- 01:16



192.168.6.2/Forms/Exan



Personal information

Student

Shahzeb
Hassan

Reg No

MB1924-1991

Scope

scope

Timer

01:40:00


Q#37

1 year old vaccinated child brought to OPD with history of recurrent loose motion for the last 4 months. There is no history of fever and vomiting and no blood in stools. Weaning was started at the age of 6 months with wheat cerelac. There is no TB contact. On examination the patient is wasted, pale and has distended abdomen. What is the most likely diagnosis.

- ☐ Intestinal TB
- ☐ Celiac Disease
- ☐ Intussusception
- ☐ Inflammatory bowel disease
- ☐ Gastroenteritis

PREVIOUS

NEXT



Important Note

- Finishing test is mandatory, exit in the mid of the test will mark the student as absent.
- If you are uploading multiple files, first zip it.
- 01:16



192.168.6.2/Forms/Exan

**Personal information****Student**Shahzeb
Hassan**Reg No**

MB1924-1991

Scope

scope

Timer

01:35:50

Q#74

What is the MINIMUM recommended duration of treatment for patients with a generalised anxiety disorder (GAD) where drug therapy has been found to be effective? Select ONE option only. Select one:

- ☐ 6 months
- ☐ 3 months
- ☐ 28months
- ☐ 12 months
- ☐ 24 months

PREVIOUS

NEXT

**Important Note**

- Finishing test is mandatory, exit in the mid of the test will mark the student as absent.
- If you are uploading multiple files, first zip it.
- 01:26



192.168.6.2/Forms/Exan

**Personal information****Student**Shahzeb
Hassan**Reg No**

MB1924-1991

Scope

scope

Timer

01:35:40

Q#76

A 30-year-old soldier is brought to ER with heat stroke having a temperature of 105°F. Which step is most important in his management?

- ☐ rapid cooling within 30 minutes with ice water immersion
- ☐ rapid cooling within 30 minutes with ice packs and sponging
- ☐ rapid cooling within 30 minutes with large fans and tepid water spray
- ☐ rapid cooling within 30 minutes with cold IV fluids
- ☐ rapid cooling within 30 minutes with multiple air coolers

PREVIOUS

NEXT

**Important Note**

- Finishing test is mandatory, exit in the mid of the test will mark the student as absent.
- If you are uploading multiple files, first zip it.
- 01:26

**Personal information****Student**Shahzeb
Hassan**Reg No**

MB1924-1991

Scope

scope

Timer

01:42:59

Q#31

A 35-year-old lady is brought to ER with fits and altered mental status. Earlier today she had taken part in a marathon on a sunny summer day. On examination her pulse is 90/m, Blood pressure is 120/80 mmHg, Temperature 98.8°F, Respiratory rate 20/m. Her investigations show a normal CT brain, Sodium 120 (Low), potassium 4 (normal) and Creatinine 0.8 (Normal). What is her diagnosis?

- ☐ Heat cramps
- ☐ Heat stroke
- ☐ Heat exhaustion
- ☐ Heat syncope
- ☐ Heat seizures

PREVIOUS

NEXT

**Important Note**

- Finishing test is mandatory, exit in the mid of the test will mark the student as absent.
- If you are uploading multiple files, first zip it.
- 01:16

**Personal information****Student**Shahzeb
Hassan**Reg No**

MB1924-1991

Scope

scope

Timer

01:36:28

Q#66

A male neonate immediately after birth was brought by his parents to the emergency department with complains of absent anal opening. After initial evaluation, the doctor on duty advised some necessary resuscitative measures and a plan of investigation was given. After 24 hours which of the following xray is performed to differentiate between low and high variety of ARM?

- ☐ A. XRAY ABD ERECT
- ☐ B. CROSS TABLE LATERAL VIEW PRONE X RAY
- ☐ C. XRAY ABD SUPINE
- ☐ D. XRAY ABD AND SPINE LATERAL VIEW
- ☐ E. XRAY ABD AND SPINE AP VIEW

PREVIOUS

NEXT

**Important Note**

- Finishing test is mandatory, exit in the mid of the test will mark the student as absent.
- If you are uploading multiple files, first zip it.
- 01:26

**Personal information****Student**Shahzeb
Hassan**Reg No**

MB1924-1991

Scope

scope

Timer

01:36:15

Q#69

A 30 year old alcoholic man presented with sudden onset epigastric pain and vomiting. His SGPT is 120 IU, serum lipase is very high, USG shows hepatomegaly. The most probable diagnosis is?

- ☐ Acute Hepatitis
- ☐ Peptic Ulcer disease
- ☐ Acid pancreatitis
- ☐ Myocardia Infarction
- ☐ GERD

PREVIOUS

NEXT

**Important Note**

- Finishing test is mandatory, exit in the mid of the test will mark the student as absent.
- If you are uploading multiple files, first zip it.
- 01:26



192.168.6.2/Forms/Exan

**Personal information****Student**Shahzeb
Hassan**Reg No**

MB1924-1991

Scope

scope

Timer

01:35:02

Q#84

Parents of a 5 month old baby come to emergency in distress with an unconscious child. You check blood glucose which turns out to be 20mg/dl. The baby took last feed 3 hrs back. After stabilizing you admit the child and order some labs. O/e the baby has doll like facies, with protuberant abdomen and isolated hepatomegaly. Lab work shows raised Triglycerides and metabolic acidosis with normal lipid profile and raised uric acid.

What glycogen storage disorder you suspect

- ☐ Von Gierke
- ☐ Pompe
- ☐ Cori
- ☐ Anderson
- ☐ McArdle disease

PREVIOUS

NEXT

**Important Note**

- Finishing test is mandatory, exit in the mid of the test will mark the student as absent.
- If you are uploading multiple files, first zip it.
- 01:26



192.168.6.2/Forms/Exan



Personal information

Student

Shahzeb
Hassan

Reg No

MB1924-1991

Scope

scope

Timer

01:35:12

Q#82

A 35-year-old man developed progressive lower extremity weakness and gait ataxia over 6 months. Neurological examination demonstrated bilateral lower extremity spasticity, increased deep tendon reflexes and bilateral Babinski signs. Sensory examination showed no sensory level but loss of proprioception and vibratory sensation in both legs with preservation of temperature and pinprick sensations. These findings are suggestive of

- ☐ Brown-Sequard syndrome
- ☐ Syringomyelia
- ☐ Vitamin B12 deficiency
- ☐ Occlusion of the anterior spinal artery
- ☐ Amyotrophic lateral sclerosis

PREVIOUS

NEXT



Important Note

- Finishing test is mandatory, exit in the mid of the test will mark the student as absent.
- If you are uploading multiple files, first zip it.
- 01:26



192.168.6.2/Forms/Exan



Personal information

Student

Shahzeb
Hassan

Reg No

MB1924-1991

Scope

scope

Timer

01:57:07

Q#5

A newborn presented to emergency with complain of respiratory distress and cyanosis, o/e abdomen is scaphoid and a visible bulge on left side of chest.o/A air entry is decreased on left side as compared to right side. xray is showing gaseous shadow on left side of chest. what is your provisional diagnosis?

- ☐ congenital lobar emphysema
- ☐ congenital cystic lesion in chest
- ☐ bronchopulmonary sequestration
- ☐ congenital diaphragmatic hernia
- ☐ lung abscess

PREVIOUS

NEXT



Important Note

- Finishing test is mandatory, exit in the mid of the test will mark the student as absent.
- If you are uploading multiple files, first zip it.
- 01:06



192.168.6.2/Forms/Exan

**Personal information****Student**Shahzeb
Hassan**Reg No**

MB1924-1991

Scope

scope

Timer

01:35:55

Q#73

7 years old girl presented to OPD with history of fever and decreased appetite for the last 5 days. The fever is low grade with associated chills. Past history is unremarkable. On examination, patient is 101°F, icteric and has soft and tender hepatomegaly. No other positive findings on examination. CBC is normal and ALT : 2500. Which investigation will help in the diagnosis of the patient?

- ☐ Dengue Serology
- ☐ Blood Culture
- ☐ HAV IgM
- ☐ Ultrasound Abdomen
- ☐ HAV IgG

PREVIOUS

NEXT

**Important Note**

- Finishing test is mandatory, exit in the mid of the test will mark the student as absent.
- If you are uploading multiple files, first zip it.
- 01:26



192.168.6.2/Forms/Exan

**Personal information****Student**Shahzeb
Hassan**Reg No**

MB1924-1991

Scope

scope

Timer

01:35:20

Q#80

A 32 years old female complains of intermittent diarrhea, chronic abdominal pain and tenesmus. She notices blood in her stools.

The most likely cause of her symptoms may be?

- ☐ Inflammatory bowel disease
- ☐ Diverticulitis
- ☐ Adenomycosis
- ☐ Urinary tract infection
- ☐

PREVIOUS

NEXT

**Important Note**

- Finishing test is mandatory, exit in the mid of the test will mark the student as absent.
- If you are uploading multiple files, first zip it.
- 01:26



192.168.6.2/Forms/Exan

**Personal information****Student**Shahzeb
Hassan**Reg No**

MB1924-1991

Scope

scope

Timer

01:52:20

Q#13

A 46-year-old male from Karachi comes to the clinic with one history of loose stools, fever and vomiting. He states that he recently returned from a trip to Swat and his wife also had similar symptoms. He has not received any vaccinations and admits to have a distant history of IV drug use and occasional alcohol. Further he reports receiving blood transfusion after a road traffic accident 3 years ago. On examination he has fever of 101 F and scleral icterus is present. Which of the following risk factors is most likely responsible for his condition?

- ☐ Alcohol consumption
- ☐ History of blood transfusions
- ☐ History of IV drug use
- ☐ Recent travel
- ☐ Unprotected sexual intercourse

PREVIOUS

NEXT

**Important Note**

- Finishing test is mandatory, exit in the mid of the test will mark the student as absent.
- If you are uploading multiple files, first zip it.
- 01:06

**Personal information**

Student

Shahzeb
Hassan

Reg No

MB1924-1991

Scope

scope

Timer

01:33:07

Q#104

According to current guidance, which is the SINGLE MOST appropriate first-line treatment for the prophylaxis of migraine? Select ONE option only.

- ☐ Sodium valproate
- ☐ Lisinopril
- ☐ Sumatriptan
- ☐ Propranolol
- ☐ pizotifen

PREVIOUS

NEXT

**Important Note**

- Finishing test is mandatory, exit in the mid of the test will mark the student as absent.
- If you are uploading multiple files, first zip it.
- 01:26



192.168.6.2/Forms/Exan



Personal information

Student

Shahzeb
Hassan

Reg No

MB1924-1991

Scope

scope

Timer

01:34:38

Q#88

A 4-year-old presents to the emergency department with a chief complaint of swelling around the eyes, ankles and abdomen. You note the patient to have pitting edema up to the knees bilaterally and peri-orbital edema with no erythema. Also there is evidence of free fluid in abdominal cavity in form of shifting dullness and fluid thrill. The patient is not jaundiced, tachypneic, tachycardiac, urine output is normal and there is no history of previous such episodes. You send off a urine analysis and find that the patient has 3+ protein in the urine without signs of infection or red blood cells. What is the most probable diagnosis?

- ☐ Angioedema
- ☐ Nephrotic syndrome
- ☐ congestive cardiac failure
- ☐ protein caloric manutrition
- ☐ chronic liver disease

PREVIOUS

NEXT



Important Note

- Finishing test is mandatory, exit in the mid of the test will mark the student as absent.
- If you are uploading multiple files, first zip it.
- 01:26



192.168.6.2/Forms/Exan



Personal information

Student

Shahzeb
Hassan

Reg No

MB1924-1991

Scope

scope

Timer

01:34:52

Q#86

A 70-year-old man is brought to the emergency department by his son because of a three weeks history of right upper quadrant abdominal pain, chills, and confusion. He has vomited twice during this time despite decreased food intake. Vital signs are temperature 102 F, pulse 110/min, respirations 18/min, and blood pressure 100/60 mm Hg. The patient appears seriously ill without evidence of jaundice. Abdominal examination is normal. Results of laboratory studies are shown: WBC 16,500/mm³ with prominent immature forms Bilirubin total 2.1 mg/dL Ultrasonography of the abdomen shows liver having hyperechoic shadows Which of the following is the most likely diagnosis?

- ☐ Acute cholecystitis
- ☐ Acute pancreatitis
- ☐ Cholangitis
- ☐ Hepatitis
- ☐ Liver abscess

PREVIOUS

NEXT

Important Note

- Finishing test is mandatory, exit in the mid of the test will mark the student as absent.
- If you are uploading multiple files, first zip it.
- 01:26



192.168.6.2/Forms/Exan

**Personal information****Student**Shahzeb
Hassan**Reg No**

MB1924-1991

Scope

scope

Timer

01:35:16

Q#81

A 45-year-old man with a history of hypertension presents with a sudden onset of severe headache, vomiting, and confusion. Examination reveals papilledema, bradycardia, and hypertension. CT of the head shows a large right-sided intracerebral hemorrhage with midline shift. What is the most appropriate initial management?

- ☐ Administer mannitol
- ☐ Emergency craniotomy
- ☐ Initiate antihypertensive therapy to reduce blood pressure aggressively
- ☐ Intubate and hyperventilate to reduce ICP
- ☐ Start antiepileptic medication prophylactically

PREVIOUS

NEXT

**Important Note**

- Finishing test is mandatory, exit in the mid of the test will mark the student as absent.
- If you are uploading multiple files, first zip it.
- 01:26



192.168.6.2/Forms/Exan



Personal information

Student

Shahzeb
Hassan

Reg No

MB1924-1991

Scope

scope

Timer

01:34:18

Q#92

You diagnose a 32 year old female with Dystonia. She has been complaining of spasms in her neck and upper torso, which at times are quite painful. She has to rely on regular pain relief and muscle relaxants to help her function on a daily basis. All her baseline investigations are normal. As you are aware, Dystonia is a condition that can affect one part of the body (focal dystonia), two or more adjacent parts (segmental dystonia), or all parts of the body (general dystonia). How would you best manage this patient?

- ☐ Current guidelines recommend treatment with medications alone
- ☐ Current guidelines recommend treatment with psychotherapy alone
- ☐ Current guidelines recommend treatment with surgery alone
- ☐ Current guidelines recommend treatment with medications and psychotherapy combination
- ☐ Current guidelines recommend treatment with medications, psychotherapy and/or surgery

PREVIOUS

NEXT



Important Note

- Finishing test is mandatory, exit in the mid of the test will mark the student as absent.
- If you are uploading multiple files, first zip it.
- 01:26



192.168.6.2/Forms/Exan

**Personal information****Student**Shahzeb
Hassan**Reg No**

MB1924-1991

Scope

scope

Timer

01:32:04

Q#113

25 year old girl of African ethnicity incidentally notices a lump in her breast 4 months ago which has grown significantly in the period till now. On examination it is a 12 * 10cm painless lobulated mobile mass, on USG examinaion it is a hypoechoic mass with no axillary lymphadenopathy. The lesion most likely is

- ☐ Inflammatory breast ca
- ☐ phyllides tumor
- ☐ breast abscess
- ☐ giant fibroadenoma
- ☐ fibrocystic disease

PREVIOUS

NEXT

**Important Note**

- Finishing test is mandatory, exit in the mid of the test will mark the student as absent.
- If you are uploading multiple files, first zip it.
- 01:26



Personal information

Student

Shahzeb
Hassan

Reg No

MB1924-1991

Scope

scope

Timer

01:34:57

Q#85

A 1 year old child presents with abdominal distention and severe pallor. he is a product of consanguineous marriage and there is history of one other sibling who is on regular blood transfusion and chelation therapy. on examination the liver and spleen are palpable but there is no shifting dullness Or fluid thrill. his Hb is 6.2 g/dL.Hb electrophoresis report shows HbF more than 90 percent. what is the most likely diagnosis?

- ☐ Iron deficiency anemia
- ☐ Thalassemia major
- ☐ Hereditary spherocytosis
- ☐ Autoimmune hemolytic anemia
- ☐ G6PD deficiency

PREVIOUS

NEXT



Important Note

- Finishing test is mandatory, exit in the mid of the test will mark the student as absent.
- If you are uploading multiple files, first zip it.
- 01:26



192.168.6.2/Forms/Exan

**Personal information****Student**Shahzeb
Hassan**Reg No**

MB1924-1991

Scope

scope

Timer

01:34:46

Q#87

An elderly laborer is brought to ER with heat stroke. On examination his pulse is 130/m, Blood pressure is 110/70 mmHg, Temperature 105°F and Respiratory rate 26/m. His GCS is 10/15. His initial investigations show renal failure, hyponatremia, hyperkalemia and deranged liver profile. Which of the following is associated with higher morbidity and mortality?

- ☐ Delays in IV fluids administration
- ☐ Delays in cooling the body temperature
- ☐ Delay in hyponatremia management
- ☐ Delay in starting hemodialysis
- ☐ Delay in mechanical ventilation

PREVIOUS

NEXT

**Important Note**

- Finishing test is mandatory, exit in the mid of the test will mark the student as absent.
- If you are uploading multiple files, first zip it.
- 01:26



192.168.6.2/Forms/Exan

**Personal information****Student**Shahzeb
Hassan**Reg No**

MB1924-1991

Scope

scope

Timer

01:35:29

Q#78

An 84 year old man presented with walking difficulty. Over the past few months he had a hard time in initiating his gait and it took him much longer to get up from a chair. On examination he took small, shuffling steps and had little arm swing. He had a resting tremor of his right arm for last 01 year. Which of the following is the most likely diagnosis?

- ☐ Essential tremor
- ☐ Normal pressure hydrocephalus
- ☐ Parkinson plus syndrome
- ☐ Idiopathic Parkinson's disease
- ☐ Secondary Parkinsonism

PREVIOUS

NEXT

**Important Note**

- Finishing test is mandatory, exit in the mid of the test will mark the student as absent.
- If you are uploading multiple files, first zip it.
- 01:26



192.168.6.2/Forms/Exan

**Personal information**

Student

Shahzeb
Hassan

Reg No

MB1924-1991

Scope

scope

Timer

01:51:18

Q#14

A 60-year-old alcoholic man is brought to the emergency department with hematemesis. His pulse is 110 beats per minute, blood pressure is 100/60 mm Hg and respiratory rate 19 per minute. Abdominal examination is significant for hepatosplenomegaly, and a distended abdomen which is tympanic on percussion. His testicles are small and a rectal examination produces guaiac-negative stool. His hematocrit is 23 percent. After placement of a nasogastric tube, 400 mL of bright red blood is evacuated. After initial fluid resuscitation, which of the following is the most appropriate next step in management?

- ☐ Barium swallow
- ☐ Blood transfusion
- ☐ Esophageal balloon tamponade.
- ☐ Exploratory laparotomy
- ☐ Upper endoscopy

PREVIOUS

NEXT

Important Note

- Finishing test is mandatory, exit in the mid of the test will mark the student as absent.
- If you are uploading multiple files, first zip it.
- 01:06



192.168.6.2/Forms/Exan



Personal information

Student

Shahzeb
Hassan

Reg No

MB1924-1991

Scope

scope

Timer

01:55:07

Q#8

A 75 years old woman is admitted with headache and vomiting. She denies abdominal pain. She reports weight loss of one stone over the last six weeks. On further questioning it becomes apparent that she has noticed the vomitus contains food from several days ago. Abdominal X ray reveals a prominent gastric bubble. Which of the following is the most likely diagnosis ?

- ☐ Acute cholecystitis
- ☐ Colon carcinoma
- ☐ Gastric outflow obstruction
- ☐ Peptic ulceration
- ☐ Raised intracranial pressure

PREVIOUS

NEXT



Important Note

- Finishing test is mandatory, exit in the mid of the test will mark the student as absent.
- If you are uploading multiple files, first zip it.
- 01:06



192.168.6.2/Forms/Exan



Personal information

Student

Shahzeb
Hassan

Reg No

MB1924-1991

Scope

scope

Timer

01:53:58

Q#9

A 20-year-old male comes to clinic with per rectal bleeding for the past 1 week. He tells you that he is worried about cancer because many of his first and second degree relatives had bowel cancer. On investigations he is found to be anemic and colonoscopy shows multiple polyps throughout his colon. You suspect Familial adenomatous polyposis. What is his risk of developing colonic adenocarcinoma?

- ☐ 50%
- ☐ 75%
- ☐ 100%
- ☐ 25%
- ☐ 10%

PREVIOUS

NEXT



Important Note

- Finishing test is mandatory, exit in the mid of the test will mark the student as absent.
- If you are uploading multiple files, first zip it.
- 01:06



192.168.6.2/Forms/Exan

**Personal information****Student**Shahzeb
Hassan**Reg No**

MB1924-1991

Scope

scope

Timer

01:31:59

Q#114

A 15 years old female presents to OPD with complaint of recurrent headache for last 4 months. She is also complaining of diplopia and pulsatile tinnitus. There is no history of vomiting or fever. On examination of fundi there is bilateral papilledema. Rest of neurological examination doesn't reveal any significant finding. Her weight is 90 kg and BP is 130/90 mmHg. What is the most probable diagnosis:

- ☐ Meningitis
- ☐ Migraine
- ☐ Pseudotumor cerebri
- ☐ Brain Tumor
- ☐ Tension headache

PREVIOUS

NEXT

**Important Note**

- Finishing test is mandatory, exit in the mid of the test will mark the student as absent.
- If you are uploading multiple files, first zip it.
- 01:26



192.168.6.2/Forms/Exan

**Personal information****Student**Shahzeb
Hassan**Reg No**

MB1924-1991

Scope

scope

Timer

01:49:42

Q#16

A 7 years old child presents to OPD with chief complaints of jaundice, vomiting and abdominal distention since last 7 months. There is a history of same symptoms in another child as well. On examination his liver is palpable 6 cm below the costal margin and spleen is palpable 4 cm below the costal margin. There is evidence of free fluid in abdominal cavity in form of positive shifting dullness and fluid thrill. What is the most probable diagnosis?

- ☐ Nephrotic syndrome
- ☐ Chronic liver disease
- ☐ Chronic kidney disease
- ☐ Acute hepatitis
- ☐ Hepatic encephalopathy

PREVIOUS

NEXT

**Important Note**

- Finishing test is mandatory, exit in the mid of the test will mark the student as absent.
- If you are uploading multiple files, first zip it.
- 01:16

**Personal information****Student**Shahzeb
Hassan**Reg No**

MB1924-1991

Scope

scope

Timer

01:48:19

Q#18

26 year old man presented with convulsive movements that continued for 10 minutes despite treatment with a total of 10 mg of lorazepam. Which of the following medications is indicated at this time?

- ☐ Propofol
- ☐ Fosphenytoin
- ☐ Diazepam
- ☐ Phenobarbital
- ☐ Chlordiazepoxide

PREVIOUS

NEXT

**Important Note**

- Finishing test is mandatory, exit in the mid of the test will mark the student as absent.
- If you are uploading multiple files, first zip it.
- 01:16



192.168.6.2/Forms/Exan

**Personal information****Student**Shahzeb
Hassan**Reg No**

MB1924-1991

Scope

scope

Timer

01:48:43

Q#18

26 year old man presented with convulsive movements that continued for 10 minutes despite treatment with a total of 10 mg of lorazepam. Which of the following medications is indicated at this time?

- ☐ Propofol
- ☐ Fosphenytoin
- ☐ Diazepam
- ☐ Phenobarbital
- ☐ Chlordiazepoxide

PREVIOUS

NEXT

**Important Note**

- Finishing test is mandatory, exit in the mid of the test will mark the student as absent.
- If you are uploading multiple files, first zip it.
- 01:16



192.168.6.2/Forms/Exan

**Personal information****Student**Shahzeb
Hassan**Reg No**

MB1924-1991

Scope

scope

Timer

01:31:28

Q#118

A neonate presented with lower back swelling since birth. Swelling is cystic in nature and transillumination test is positive. Diagnosis of meningocele is made. Which of the deficiency in mother leads to this anomaly in neonates?

- ☐ vit A deficiency
- ☐ vit B12 deficiency
- ☐ vit C deficiency
- ☐ folic acid deficiency
- ☐ vit D deficiency

PREVIOUS

NEXT

**Important Note**

- Finishing test is mandatory, exit in the mid of the test will mark the student as absent.
- If you are uploading multiple files, first zip it.
- 01:26